

Vascular Anomalies: A Cased-based Discussion

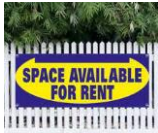Colin Fuller, MD, MS
Assistant Professor of Otolaryngology

OKAFP Meeting
August 24, 2023



Relevant Disclosure and Resolution

I have no relevant financial relationships or affiliations with commercial interests to disclose.



Patient Photography

This presentation includes copyrighted patient photographs, which are used with the permission of publishers. Patient identities have been obscured to the extent possible. Additional patient photographs from my practice are used with the expressed permission of each patient and/or family for the purpose of this presentation.

Viewers/readers may view, browse, and/or download material, provided these uses are for noncommercial personal purposes. Except as provided by law, this material may not be further reproduced, distributed, transmitted, modified, adapted, performed, displayed, published, or sold in whole or in part, without prior written permission.



All about me!

- Father of 2, husband to another physician
- Originally from FW, TX
- Otolaryngology residency in Augusta, GA
- Pediatric fellowship in LR, AR
- Training in...
 - ...general pediatric ENT
 - ...cleft lip and palate surgery
 - ...care for complex vascular anomalies



Why ENT?

- Vascular anomalies may occur anywhere
- Who takes the lead?
 - Orthopedics (Peds? Onc?)
 - General surgery
 - ENT (Peds? H&N?)
 - IR
 - Heme/onc
- Vascular anomalies occur ~50% in the head and neck, meaning ENT providers have an opportunity to lead the team

Our team



Vascular anomalies

- A broad term that encompasses neoplastic and non-neoplastic lesions of blood and lymphatic vessels.
- First, a history lesson...



- ISSVA, was initially founded in 1992 in part to help to clarify the nomenclature of vascular anomalies so that various disciplines could begin to speak the same language.
- Beware! Various holdovers from prior to this era persist...

J Clin Med. Pathol. 2014 Sep; 18(Suppl 1): S117-S120
doi: 10.4103/0974-2026.141332

Update on the classification of hemangioma

Antony Garcia, Verónica Massi¹ and Ahmed Nasif²

CONCLUSION

Therapeutic guidelines, management and follow-up of hemangiomas and vascular malformations differ and are beyond the scope of this article. A good classification is important for categorizing information, recording data, proper communication, guiding treatment plans, obtaining prognostic information and should be easy to understand and applied by the clinician. It is our aim to be consistent in our terminology and classification of vascular lesions in all our scientific writings and presentations in order to communicate effectively, understood by pathologists, promote research and develop better therapeutic. Terms to be avoided when describing these lesions include angiosarcoma, hemolytic capillary hemangioma, cavernous hemangioma, pyogenic hemangioma, granular hemangioma and inappropriate nonspecific use of the terms hemangioma and vascular malformation.

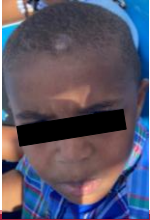

WHAT IS A CAPILARY HEMANGIOMA?

A capillary hemangioma (cavernous hemangioma) is a benign tumor consisting of an abnormal overgrowth of tiny blood vessels. Capillaries present at birth, but disappear within the first 6 months of life. They are 1-2 mm in size and then they begin to decrease in size between 12-24 months, nearly completely by 5 or 6 years of age. Capillary hemangiomas present on the face and on the skin.

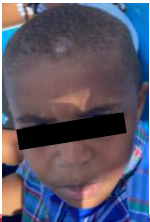

Case #1

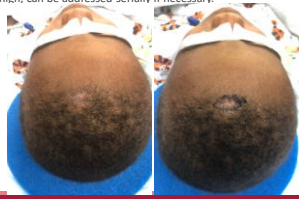

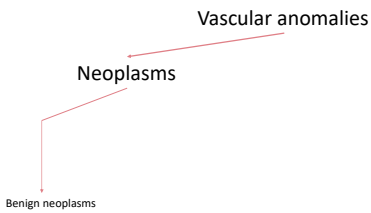
5 yo m with persistent skin who underwent course of propranolol in infancy. Not present at birth but rapid growth starting at about 1 m/o, stabilizing at about 6 m/o. Previously was much more protrusive, but seems to have stopped shrinking and stabilized.
Lesion involves scalp with minor extension onto forehead, taller than it is wide

- Dx: Infantile hemangioma
 - Vertical elliptical incision with extension onto forehead oriented perpendicular to relaxed skin tension lines
 - Very long horizontal incision just behind the hairline, including lots of uninvolved skin to appropriately distribute tension
- Or...



... serial excision. Almost all surgically-resectable lesions discussed today are benign, can be addressed serially if necessary.





ISSVA Classification of Vascular Anomalies ©2018 International Society for the Study of Vascular Anomalies Available at "issva.org/classification" Accessed August 4, 2021

Benign vascular neoplasms

- Infantile hemangioma
- Congenital hemangioma

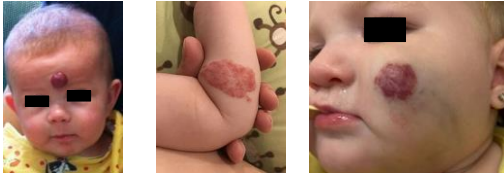

Image source Hochman, Marzillo. (2012). Management of Vascular Tumors. Facial plastic surgery. PPS, 28, 584-9. 10.1055/s-0012-122893.

* - Growth is the best clinical factor for delineating between IH and CH

Infantile hemangiomas (IH)

- IHs are the most common tumor of infancy, affecting roughly 1 in 10 <1y
- On histopathology, lesions are GLUT-1 positive (?placental "metastasis"?)
- Lesions most often involve skin and immediate subcutaneous tissues
- Diagnosis is usually clinical, though CT with contrast or MRI might be considered, or trial of beta blockers

Growth pattern:

- While some are actually present at birth (leading to confusion with congenital hemangiomas), most IHs appear and start growth phase in the first month of life*
 - Growth peaks around 5-6 months
 - Long period of involution up to 2-3 years of age
- * Because natural progression is toward eventual involution, observation and watchful waiting is the most common recommendation...

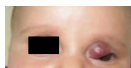Jacobs AH, Walton RG. The incidence of birthmarks in the neonate. Pediatrics. 1976;58(2):218-222.

Infantile hemangiomas (IH)

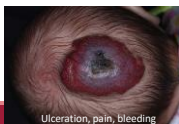- Because natural progression is toward eventual involution, observation and watchful waiting is the most common recommendation...
- But what if we can't just watch and wait for involution? Significant symptoms from:
 - Mass effect
 - Rapid growth and ulceration
 - Hypothyroidism (when multiple or especially large) due overexpression of type 3 Iodothyronine deiodinase



Stridor



Vision Loss



Ulceration, pain, bleeding

Image Source: Head and Neck Vascular Anomalies. Richter GT, Suen JY. 2015

Infantile hemangiomas (IH)

- Medical therapies
- Beta blockers

- Glucocorticoids

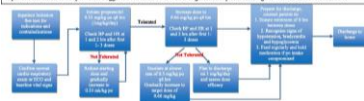Infantile hemangiomas (IH)

- Medical therapies
- Beta blockers
 - Propranolol – usually PO but also available IV. For patients <8 weeks AGA, inpatient monitoring is recommended by “current” consensus...

Infantile hemangiomas (IH)

PEDIATRICS

- Medical therapy
- Beta blockers
- Propranolol – monitor| **Required histories of Propranolol: Required for infants < 8 weeks of postnatally corrected age or with co-morbid conditions.**



Infantile hemangiomas (IH)

- Medical therapies
- Beta blockers
 - Propranolol – usually PO but also available IV. For patients <8 weeks AGA, inpatient monitoring is recommended by "current" consensus, EKG also routinely prior to starting therapy, but some emerging data indicate that this may be unnecessary. (2mg/kg/day is 1/7th therapeutic cardiac dose)
 - Timolol – topical beta blocker adapted from ophthalmology (glaucoma)
 - Atenolol? Cardioselective with possibly lower SE profile. Not as well established. Daily dose
- Glucocorticoids – injections can be used to speed progression of involution phase or when urgent reduction in size is indicated (such as in airway hemangiomas)
- Oral preparations can be considered but rarely suitable for long-term use



Infantile hemangiomas (IH)

- Surgical excision to resect residuum after involution
- Laser therapy can be considered to make the lesion paler, but is not usually a definitive treatment
- May be useful for large, persisting lesions or for acute bleeding or ulceration



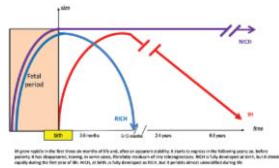
Congenital Hemangiomas (CH)

- Present at birth and do not grow
- Much less common than IH
- Overwhelming majority of CH are rapidly-involuting CHs (RICHs), as opposed to very rare non-involuting CH (NICH)
- Congenital lesions have a much broader differential – may require imaging to confirm diagnosis depending on location
- Later in life, patients with NICH may complain of pain in the location of the lesion, prompting consideration of surgical resection
- No known medical therapies for treating CHs



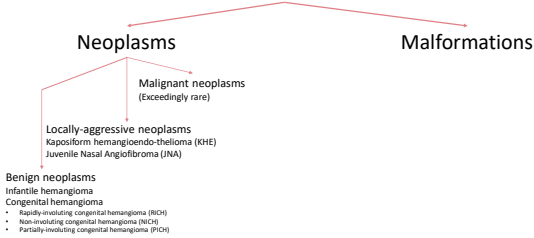
IH vs CH

- IHs grow with time, CHs do not
- IHs are much more common!
- Morphologically indistinct
- Histopath: IH +ve for GLUT-1
- Diagnostic course of propranolol (or atenolol?) can be considered if clinically necessary to differentiate – beware of missing a sinister diagnosis



Gelmetti, C. Vascular Birthmarks: A hidden world behind a word. Indian J of Ped Derm. 2018, Jan[19]:1-8.

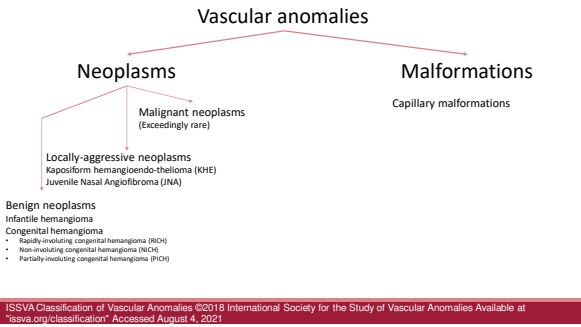
Vascular anomalies



ISSVA Classification of Vascular Anomalies ©2018 International Society for the Study of Vascular Anomalies Available at issva.org/classification/. Accessed August 4, 2021

Vascular malformations

- Distinct from vascular tumors
- Often congenital lesions, arising from aberrant lymphatic, arterial, venous or capillary growth



Capillary malformations (CM)

- Congenital, **well-defined** vascular macule or patch (non-elevated discoloration)
- Most common head-and-neck vascular malformation
- AKA "port-wine stain"
- Dilatation or ectasia of dermal capillaries
- Unless a mixed lesion with other vascular malformations, CMs do not protrude from the skin but the surrounding skin may be slightly thickened, do not bleed significantly
- Functional limitations are uncommon but may be disfiguring
- Dx is usually clinical. Imaging usually not required

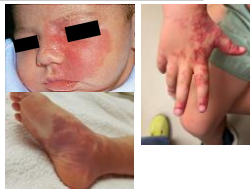

Image Source: Head and Neck Vascular Anomalies, Richer, DT, Sarr, JP, 2015
 Photo: Peter Tschopp for Wikimedia.org via GFDL. Wikimedia, March 2, 2014.

Capillary malformations (CM)

- Large "segmental" capillary malformations should prompt workup for Sturge-Weber syndrome (MRI, ophthalmology referral)
- Large CM (usually centered on the ophthalmic division of trigeminal nerve)
- Glaucoma
- Leptomeningeal vascular malformation
- May also occur in vascular anomaly syndromes including Klippel-Trenaunay syn (KTS)

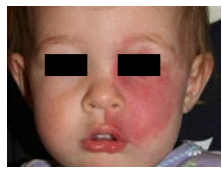

Image source: American Association for Pediatric Ophthalmology and Strabismus. Available from: <http://apps.wiley.com/wiley-sturge-weber-syndrome> [accessed 17 Aug. 2021]

Nevus simplex, or medial CM

- Light pink skin lesion located anywhere in continuity from glabella-scalp-midline back-sacrum, often V-shaped on the forehead, may involve nose or medial eyelids
- This lesion is histologically indistinct from capillary malformation, but more mild
- Usually lightens with time and does not require treatment
- May be treated if still persistent after age ~2

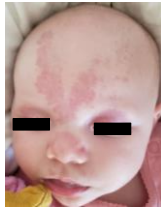

Image source: American Association for Pediatric Ophthalmology and Strabismus. Available from: <https://aapos.org/glossary/oculocutaneous-syndrome> [accessed 17 Aug. 2023].

CM management

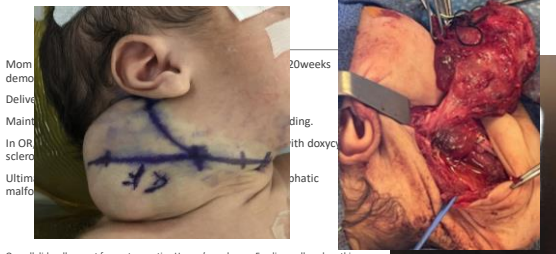- Decision to intervene depends on patient and parent preference – mostly a cosmetic concern, few functional limitations
- Medical therapy – Sirolimus (rapamycin)
 - Inhibits mammalian target of rapamycin (mTOR)
 - Oral or topical preparations
 - If systemic, requires monitoring, dose titration, prophylactic abx (p. carinii infection)
- Laser therapy



May 21, 2023

The Dirty Drug and the Ice Cream Tub

Play • 46 min



Mom demo
Deliver
Maintain
In OR
sclerotic
Ultimate
malformation

20 weeks
ding.
with doxycy
phatic

Overall did well, except for post-operative Horner's syndrome. Feeding well, no breathing concerns!

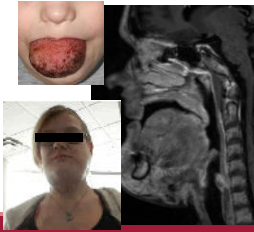21 yo f with extensive surgical history including previous tracheostomy (now decannulated), tongue reduction, multiple open neck surgeries who presents to clinic with known history of lymphatic malformation and progressive oral pain and snoring

No known history of sclerotherapy. Repeat MRI with involvement of oral tongue, Bot, and perimandibular tissue

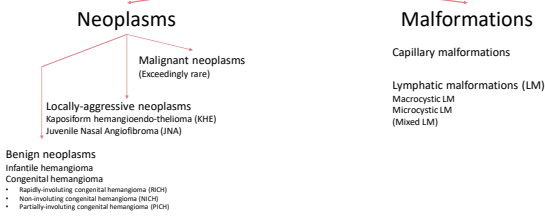What treatment options should we offer? Why is this different from previous patient?

- Microcystic LM
- Injection sclerotherapy and oral tongue coblation for mucosal involvement
- Rarely a great candidate for excision

Completed third round of sclerotherapy (often performed in series)



Vascular anomalies



ISSVA Classification of Vascular Anomalies ©2018 International Society for the Study of Vascular Anomalies Available at issva.org/classification/. Accessed August 4, 2021

Lymphatic malformations (LMs)

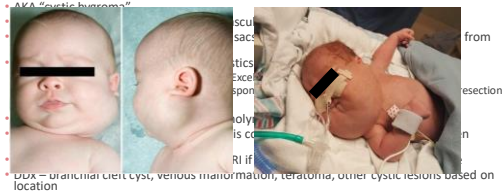

Image Source: Head and Neck Vascular Anomalies, Richier OJ, Sam JI, 2015

Lymphatic malformations (LMs)

- For small isolated lesions with high confidence in the diagnosis and minimal functional limitations, watchful waiting may be an appropriate approach
- Spontaneous regression has been demonstrated to be more common in head and neck lesions that are lateralized, infrahyoid and macrocystic (Secondary infection can induce involution in some lesions)
- Unfortunately, lateralized, infrahyoid macrocystic lesions are also more amenable to surgical resection and sclerotherapy than higher, medial microcystic lesions
- Surgical excision of primarily macrocystic lesions, or of macrocystic component of mixed lesions
- Sirolimus (usually for extensive or multifocal lesions, esp as result of syndrome)
- Sclerotherapy

Bonilla-Velez J, et al. Active Observation as an Alternative to Invasive Treatments for Pediatric Head and Neck Lymphatic Malformations. *Laryngoscope*. 2021 Jun;131(6):1392-1397.

Sclerotherapy for vascular anomalies

- "Scarring therapy" for lymphatic, venous or arteriovenous malformations
- Chemical irritant injected into and/or around vascular anomaly to induce scarring of vessel channel and/or surrounding tissue. Reduces burden of disease/limits lesion growth
- In pediatric patients, virtually always under anesthesia for better control of delivery
- Sometimes necessitates ultrasound or other image guidance (IR)
- In venous or AV malformations requiring laser therapy, may be performed in conjunction (surgeon)
- Specific agents (increasing pain/inflammation, some feel this increases efficacy)
 - Bleomycin – antineoplastic agent
 - Doxycycline – antibiotic
 - OK-432 (streptococcal antigen developed and used in Japan)
 - Sodium tetradeceyl sulfate (STS)
 - Ethanol

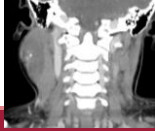

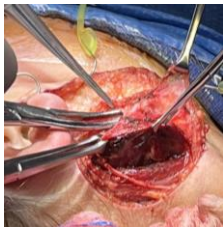Sclerotherapy for vascular anomalies

- As we will discuss, indications include:
 - LMs
 - VMs
 - AVMs
- IR (justifiably) feels it is critical to directly inject the lesions without any "spill" around the malformation
- However, microcystic LMs are known to improve from injection sclerotherapy, where the injection is both in and around the lesion

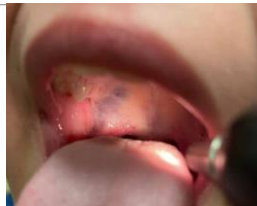

- 10 yo f with h/o progressive R facial swelling for 5 years, previously diagnosed as a parotid hemangioma and parotid lymphatic malformation. Now with progressive right facial pain/tenderness.
- Able to induce acute swelling with jaw clenching or Valsalva.
- CT neck with contrast
- Venous malformation of parotid
- Tx options
 - Skin surface not involved, lesion is deep in parotid, laser therapy not indicated
 - Could consider sclerotherapy
 - Referred to IR for percutaneous embolization with immediate superficial parotidectomy under same anesthesia

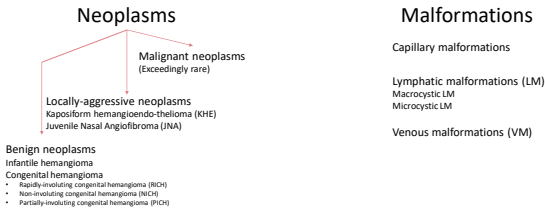



- 8 yo male who was incidentally found on exam to have purple staining of the right aspect of the oropharynx
- Asymptomatic
- MRI confirmed venous malformation involving right oropharynx and pterygoid plexus
- Tx
 - Do nothing?



Vascular anomalies



ISSVA Classification of Vascular Anomalies ©2018 International Society for the Study of Vascular Anomalies Available at issva.org/classification/ Accessed August 4, 2021

Venous malformations (VM)

- Dilated venous channels with (often a network of) thin-channeled walls and abnormal smooth muscle
- Slow flow of blood with poor drainage, resulting in expansion of the lesion to invade or impinge on normal tissue
- Unlike LMs, VMs do not regress spontaneously
- Multimodal distribution of presentation – congenital, early puberty, pregnancy
- Women with history of venous malformation (in remission or active disease) should be on estrogen-sparing contraception

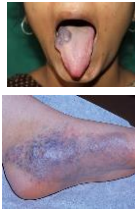

Image Source: Color Atlas of Pediatric Dermatology, Swann, Neil & Price, second edition Copyright 2008
 Social Media Strategy: Scientific Figure on ResearchGate. Available from: https://www.researchgate.net/publication/316667077 [accessed 17 Aug. 2021]

Venous malformations (VM)

- Symptoms depend on location of the lesion and resultant mass effect
- Mucosal surfaces may bleed, cutaneous bleeding is less common
- Lesions may be painful when localized thrombosis occurs ("phleboliths")
 - High risk of LIC in large lesions
 - D-dimer is often elevated
- Hematology involved to assist with anticoagulation (to reduce pain while definitive management is rendered, may also prevent thrombus perioperatively for IR sclero)

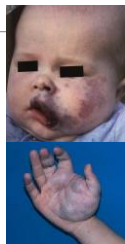
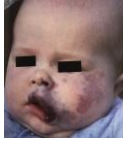
Image Source: Hand and Feet Vascular Anomalies, Bhatia, D, 2015
 KJOM Dermatology 2017 Apr; 36(2): 141-54. PMID: 27504848

VM treatment

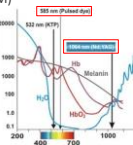
- Similar to lymphatic malformations:
 - Sirolimus for residual/diffuse lesions
 - Sclerotherapy
 - Surgical resection – often immediately following IR embolization
 - Laser
- Generally, surgery can/should only proceed once overlying epithelium has been cured of involvement with laser treatments – reduces morbidity of reconstructive procedures, VASTLY improves cosmetic result



Principles of Laser and Sclerotherapy for Vascular Anomalies, Richard C. G. Sun W. 2023.

Laser therapy for vascular anomalies

- Selective photothermolysis
- Takes advantage of differential between Ox-Hgb and Deox-Hgb absorption spectra
- Pulsed-dye laser for “red” lesions (hemangiomas, AVMs, CM)
- ND:YAG for “blue” lesions (VM, CM, AVMs)
- ND:YAG has deeper penetration (less melanin absorption)

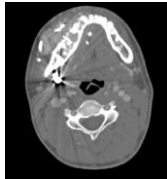


Laser and Sclerotherapy for vascular vascular malformations

- Often, combined laser/sclerotherapy 3-4 sessions are scheduled q3 months, then re-assess for response
- Laser is important for reducing morbidity of surgical resection (epithelium-sparing surgery)
- Sclerotherapy may also be delayed until after resection (resection may be more challenging after sclerotherapy, especially if done “blindly”)



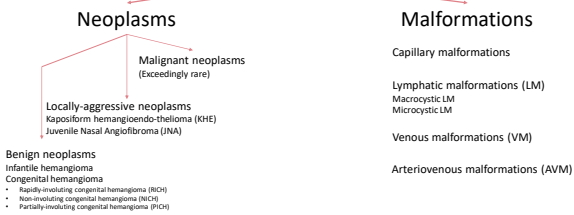
13 yo m with known history of mandibular AVM presents to ED with profound oral cavity hemorrhage 6 months after undergoing coil embolization which provided temporary control of the same. CTA demonstrates mandibular marrow space AVM with extension into perimandibular lower lip.



Tx options?

- Stop the bleeding. Ideally with a selective temporizing embolization and/or laser
- Curative resection after embolization (radical resection vs curettage?)

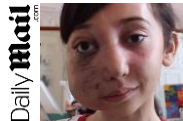Vascular anomalies



ISSVA Classification of Vascular Anomalies ©2018 International Society for the Study of Vascular Anomalies Available at issva.org/classification/. Accessed August 4, 2021

Arteriovenous malformations (AVM)

- Most difficult vascular anomaly to treat, thankfully also the rarest
- May be thought of as arteriovenous fistula, with a nidus of abnormal capillaries that shunt oxygenated blood in a high-flow fashion
- Because of shunting, surrounding tissue is chronically paradoxically ischemic, leading to neovascularization and growth of the lesion, as well as enlargement of feeding/draining vessels
- Symptoms usually related to bleeding, which can be hemodynamically significant and life-threatening – late stage includes high-output HF



Beauty vlogger, 11, with severe facial disfigurement becomes YouTube star by sharing her make-up tips with millions of fans

- 11yo has AVM, an abnormal connection between arteries and veins
- She has had 20 major operations and more than 200 hospital visits
- Started YouTube channel when she was eight and now has 2 million views
- The 11-year-old from London has helped raise more than \$60,000

Available from <https://www.dailymail.com/news/health/article-3880122/11-year-old-beauty-vlogger-45-000-subscribers.html> [accessed 17 Aug. 2021]

Arteriovenous malformations (AVM)

- AVMs may present in infancy and can be mistaken for IH, which are also imaged
- AVMs do not have the appearance of IH and
- On exam, AVMs usually bluish-purple, IHs do not

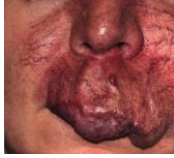
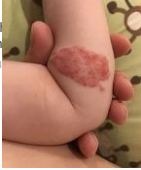
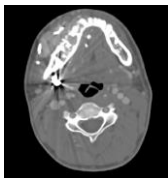
Image Source: Head and Neck Vascular Anomalies, Richter CJ, Sun W, 2015.

AVM treatment options

- Laser therapy for epithelial involvement (same rule regarding epithelium-sparing surgery for VM applies here)
- Sclerotherapy
- Embolization/resection if focal and surgically accessible. For arterial embolizations, wake patient up afterward for neuro exam pre-operatively (defensive medicine)
- For acute bleeding, laser therapy may be used, esp for mucosal bleeding
- Embolization should be super-selective – large feeding vessels should be spared if possible for future access. AVM will virtually always recruit from adjacent vasculature later.



13 yo m with known history of mandibular AVM presents to ED with profound oral cavity hemorrhage 6 months after undergoing coil embolization which provided temporary control of the same. CTA demonstrates mandibular marrow space AVM with extension into perimandibular lower lip.



Tx options?

- Stop the bleeding. Ideally with a selective temporizing embolization and/or laser

- Curative resection after embolization (radical resection vs curettage?)



Peer Review Log: 2019 Apr 12(06):1105-1114. doi: 10.1007/s12019-019-1080-5

Extracranial arteriovenous malformations: natural progression and recurrence after treatment

Allen J Liu,†, John B Mulliken, David Zornikowski, Steven J Fishman, Aviv G Geaney
 JAMA Facial Plast Surg. 2019;21(5):367-375.
 PMID: 30255868 DOI: 10.1097/FPS.0000000000000870

AVM prognosis

Largest case series on extracranial AVMs, from Boston Children's Hospital vascular anomalies center

Extremely high rate of recurrence, timeframe dependent on the lesion stage and mode of treatment

No data on frequency of using laser or sclerotherapy, reduction of recurrence/progression rate

Measuring success based on recurrence rate alone may be wrong-headed?

Table 4. Time to Recurrence after Treatment of Arteriovenous Malformation*

	Embolization Only (n = 258)	Resection with or without Embolization Recurrences (%) (n = 97 Recurrences) (%)
<1 year	21 (8.1)	55 (56.3)
1-5 years	31 (12.4)	29 (29.9)
6-10 years	4 (1.6)	8 (8.2)
>10 years	0 (0.0)	3 (3.2)

*Time to Recurrence (with or without embolization) is associated with a longer time to recurrence (P < 0.001).

Original Research HEAD AND NECK SURGERY

ORIGINAL RESEARCH HEAD AND NECK SURGERY

Clinical course of arteriovenous malformations of the head and neck: A case series

Gresham T Richter, MD, and James Y Suen, MD, Little Rock, AR

Table 3
 Therapeutic management of extensive head and neck AVMs

Pt	Embolization	No. of resections	Last resection (tu yrs)	Outcome
1	Yes	3	0	1
2	Yes	10	2	2
3	Yes	2	4	1
4	No	1	2	2
5	Yes	0	1	2
6	No	1	0.75	1
7	Yes	7	1.5	2
8	Yes	6	1	3
9	No	2	4	1
10	Yes	3	1	3

Outcome denotes previously reported by Wu et al:¹¹ 1 = controlled disease; 2 = improved disease (resective expansion); 3 = persistent or stable disease (either improved or worsened); and 4 = recurrent or worsened disease.

International Journal of Pediatric Otorhinolaryngology
 Volume 10, Number 2, 2016

Systematic review of pediatric mandibular arteriovenous malformations

doi:10.1097/OTO.0000000000000132

AVM prognosis

This terrible prognosis is contradicted by other, smaller case series demonstrating drastically better results

10-patient case series of AVM patients who'd failed prior treatment with other centers, all with improved or stable disease and improved QoL at last f/u

Quite prone to publication bias!

Limited resection may afford lower morbidity especially if revision surgery is so often necessary.

AVM treatment paradigm has shifted from treating to cure toward managing the disease with expectation of repeat therapy in a more controlled setting

Medical management of vascular malformations

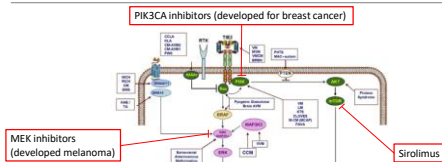
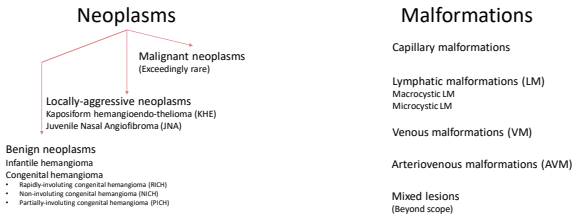


Fig. 1. Signaling pathways in vascular anomalies. PI3K, phosphoinositide-3 kinase.

Adams DM, Rice RW. Vascular Anomalies: Diagnosis of Complicated Anomalies and New Medical Treatment Options. Hematol Oncol Clin North Am. 2019 Jun;33(3):455-470. doi: 10.1016/j.hoc.2019.01.011. PMID: 31130813

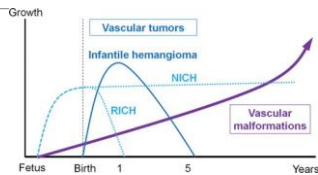
Vascular anomalies



ISSVA Classification of Vascular Anomalies ©2018 International Society for the Study of Vascular Anomalies Available at "issva.org/classification" Accessed August 4, 2021

Tissue hypertrophy

- Many vascular anomalies can present with surrounding tissue hypertrophy
- Etiology may be multifactorial
 - Somatic mutation involving surrounding tissue?
 - Increased blood flow to involved area promoting asymmetric growth?
 - Known component of vascular anomaly syndromes
 - Klippel Trenaunay (KTS), Diffuse capillary malformation with overgrowth (DCMO), many others
- Involved extremities (especially lower extremities) may require growth plate arrest (epiphysiodesis) during adolescence
- Surgical approach may be complicated by the presence of the lesion, requiring multidisciplinary coordination



Syndromes Associated with Vascular Tumors and Malformations: A Pictorial Review Taiki Nozaki, et al. RadioGraphics 2013;33:1, 175-195

Conclusion and Clinical Pearls

- Infantile hemangiomas (IHs) are the most common vascular anomaly, and follow a predictable pattern of early growth and late involution.
- IHs that require treatment often respond well to propranolol during the early proliferative phase. Atenolol is an emerging treatment option that may have fewer side effects.
- IHs grow, congenital hemangiomas (CHs) do not. CHs are overwhelmingly most likely to be rapidly-involuting CHs (RICHs) that also will likely not require treatment.
- Vascular malformations, on the other hand, typically do not involute spontaneously, with the exception of select lymphatic malformations.



Additional Resources

- ISSVA Classification of Vascular Anomalies ©2018 International Society for the Study of Vascular Anomalies Available at "issva.org/classification".
- Head and Neck Vascular Anomalies: A Practical Case-Based Approach. Richter GT, Suen JY. 2015. Plural Publishing, San Diego, CA.
- Very happy to chat about any referrals for vascular lesions with unclear diagnoses, and happy to see patients vascular lesions outside head and neck or in adults!
- Many referrals are funneled through orthopedics or through dermatology, but if wait times are long or urgency is critical, please feel free to contact me:
- Colin-fuller@ouhsc.edu
- 817-454-1615 (cell)



Thank you!



Questions

